ELECTROSURGICAL POCKET GUIDE FOR GI INTERVENTIONS

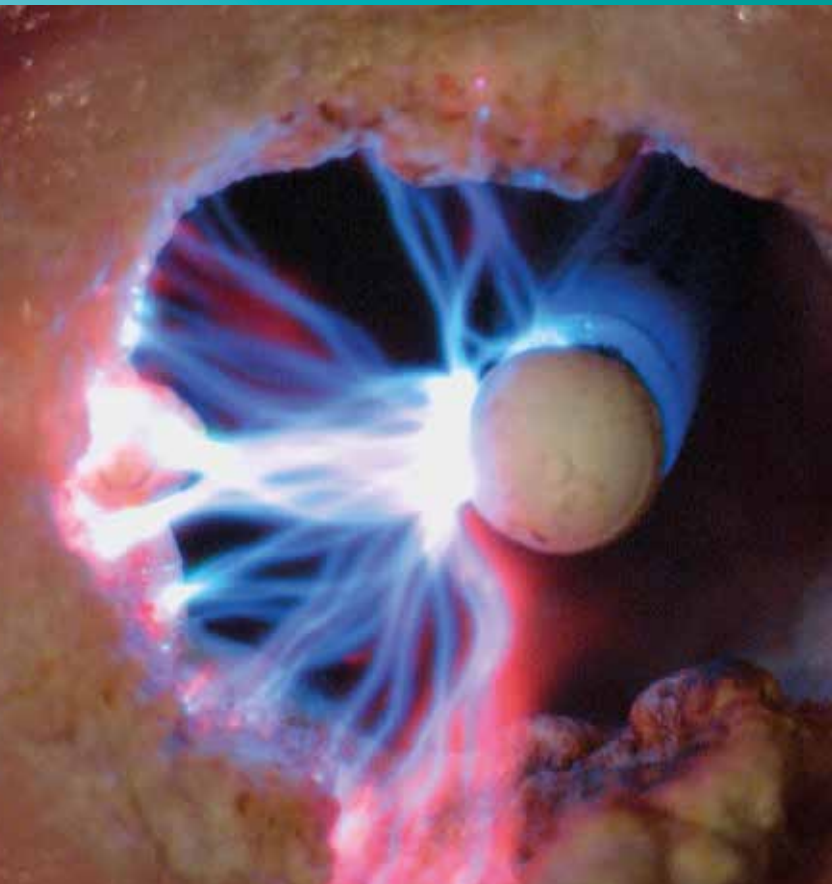

FOREWORD

High-frequency (HF) currents have been known for more than 100 years. As far back as 1890, Tesla, Nernst and d'Arsonval carried out the first experiments dealing with the physiological effects of high-frequency, high-voltage currents. Modern medicine would simply be unthinkable without high-frequency currents in surgery. The first and foremost aim of electrosurgery has always been maximum safety for patients, users and third parties. Enormous efforts worldwide have been undertaken in this field to minimize the hazards posed to all of these groups of people.

In order to use the electrosurgical means with maximum benefit, it is important to know the principles of electricity like voltage, current and impedance, especially in the endoscopic unit.

The electrosurgical generator is the source of the electron flow and voltage. The current circuit is composed of the generator, active electrode (instrument), patient and patient return electrode. The patient's tissue provides the impedance, producing heat as the electrons overcome the impedance.

This pocket guide will help the reader to understand the complex technology of electrosurgery in an easy and comprehensible way. It consists of two main parts. In the first part, the most important principles of electrosurgery will be introduced, whereas in the second part common applications will be described in a systematic manner, with the aim to make the everyday user of electrosurgery understand what they are doing and, therefore, improve the patient's outcome. It can be used as a reference book for everyday work.

Alessandro Repici

Digestive Endoscopy Unit, IRCCS Istituto Clinico Humanitas, Rozzano (Milan), Italy

Axel Eickhoff

Medizinische Klinik II, Hanau, Germany

Hendrik Manner

Dr. Horst Schmidt Kliniken, Wiesbaden, Germany

Markus D. Enderle

Erbe Elektromedizin GmbH, Tübingen, Germany

1 WHAT IS ELECTROSURGERY?
2 TISSUE EFFECTS
3 TECHNOLOGICAL ASPECTS
4 ELECTROSURGICAL INSTRUMENTS
5 ELECTROSURGICAL MODES
6 EVERYDAY ELECTROSURGICAL QUESTIONS
7 TROUBLESHOOTING
8 HANDLING OF RETURN ELECTRODES
9 POLYPECTOMY WITH SNARES
10 ENDOSCOPIC MUCOSAL RESECTION (EMR)
11 ENDOSCOPIC SUBMUCOSAL DISSECTION (ESD)
12 PAPILLOTOMY/SPHINCTEROTOMY
13 THERMAL HEMOSTASIS
14 ARGON PLASMA COAGULATION (APC)
15 DRAINAGE OF PANCREATIC CYSTS
16 NATURAL ORIFICE TRANSLUMINAL ENDOSCOPIC SURGERY (NOTES)

AUTHORS

Axel Eickhoff[1], Alessandro Repici[2], Hendrik Manner[3], Karel Caca[4], Arthur Schmidt[4] , Markus D. Enderle[5], Alexander Neugebauer[5], Ulrich Biber[5], Hartmut Hahn[5], Sabine Weinmann[5], John Day[6]

[1] Klinikum Hanau

Medizinische Klinik II, Gastroenterologie und Infektionsbiologie
Leimenstr. 20, 63450 Hanau, Germany

- axel_eickhoff@klinikum-hanau.de

[2] Digestive Endoscopy Unit

Istituto Clinico Humanitas
Via Manzoni 56, 20089 Rozzano, Italy

- alessandro.repici@humanitas.it

[3] Dr. Horst Schmidt Kliniken

Ludwig-Erhard-Str. 100, 65199 Wiesbaden, Germany

- hendrik.manner@HSK-Wiesbaden.de

[4] Klinikum Ludwigsburg

Posilipostraße 4, 71640 Ludwigsburg, Germany

- karel.caca@kliniken-lb.de
- arthur.schmidt@kliniken-lb.de

[5] Erbe Elektromedizin GmbH

Waldhörnlestraße 17, 72072 Tübingen, Germany

- markus.enderle@erbe-med.com
- alexander.neugebauer@erbe-med.com
- ulrich.biber@erbe-med.com
- hartmut.hahn@erbe-med.com
- sabine.weinmann@erbe-med.com

[6] Erbe USA, Incorporated

2225 Northwest Parkway, Marietta, Georgia 30067, USA

- john.day@erbe-usa.com

PART I

BASICS OF ELECTROSURGERY

Modern surgery is not possible without the use of high-frequency (HF) current. Part I of the pocket guide deals with the technical basics of electrosurgery. Here, the physical principles of cutting, coagulation and hemostasis as well as their influencing factors are described.
Generator technology, electrosurgical modes, surgical instruments and practical aspects, e.g. the handling of a neutral electrode or troubleshooting with the use of electrosurgery, are described systematically.

WHAT IS ELECTROSURGERY?

Physical terms

ENERGY: HEAT		
Induces rise of temperature	~ temperature difference	Joule (J)
ENERGY: WORK		
Mechanical work	force × distance	Joule (J)
VOLTAGE		
Energy necessary to separate positive and negative electrical charges, per unit charge. The voltage drives the current.	$\frac{\text{energy}}{\text{electrical charge}}$	Volt (V)
CURRENT		
Quantity of flowing charge per unit time	$\frac{\text{electrical charge}}{\text{time}}$	Ampère (A)
RESISTANCE		
Required driving voltage per current	$\frac{\text{voltage}}{\text{current}}$	Ohm (Ω)
POWER		
Energy per unit time	$\frac{\text{energy}}{\text{time}}$ = voltage × current	Watt (W)

1. WHAT IS ELECTROSURGERY?

Electrosurgery (or radiofrequency (RF) surgery, high-frequency (HF) surgery) is the use of high-frequency electrical current on biological tissue with the goal of creating a thermal effect that is medically useful.

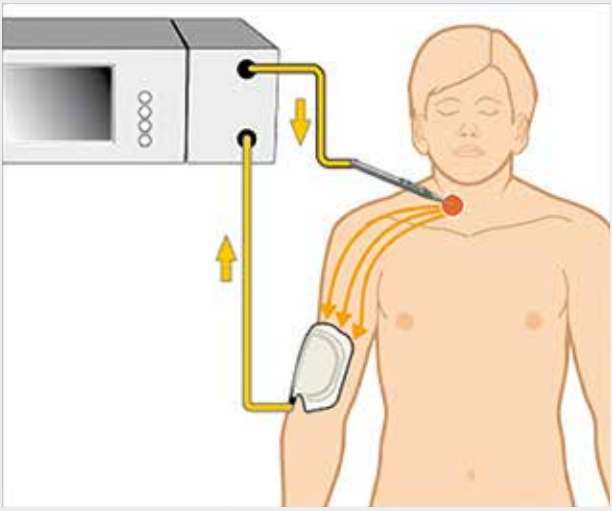

Fig. 1.1 Principle of electrosurgery: The surgical effect arises by heating due to electrical current flow (yellow arrows)

How does it work?

The patient is connected to the electrosurgical unit through two electrodes (see Fig. 1.1). The device creates electrical voltage between the electrodes. Because biological tissue is electrically conductive, current flows between the electrodes through the patient's body. The electrical circuit is therefore closed. The current generates the required heat in the tissue for the electrosurgical effect.

Important factors for the tissue effect:

- Duration of exposure
- Temperature
- Rapidity of heating

PHYSICAL BASICS

Positive and negative charges attract each other: there is a voltage between them. If there is a completed circuit, they move towards each other, i.e. current flows. Due to the electrical resistance of the conductive medium, heat is generated.

TISSUE EFFECTS

2.1 CUTTING AND COAGULATION – OVERVIEW

Electrosurgical procedures lead to various tissue effects depending on the electrosurgical instrument, the energy transmitted to the biological tissue and the time of application (Fig. 2.1).

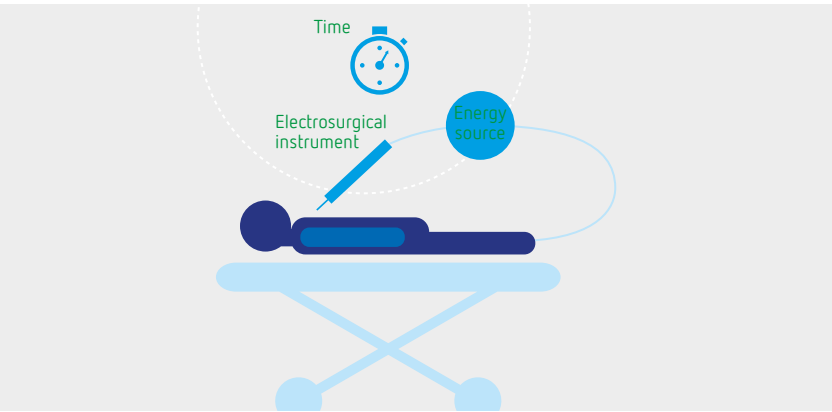

Fig. 2.1 Electrosurgery in the clinical situation

TISSUE EFFECTS

There are two main electrosurgical procedures:

CUT
The tissue is rapidly heated beyond 100 °C. The fluid vaporizes abruptly and cell structures are broken.
The required current density is provided by electric sparks between the electrode and tissue.
COAGULATION
The tissue is heated more gently and no violent structure destruction occurs.
At temperatures beyond approximately 50 °C, the tissue is irreversibly damaged (devitalized).
Beyond 80 °C, proteins are denatured (coagulated), and the tissue desiccates and shrinks.
Coagulation can be used for: • hemostasis • tissue coagulation • vessel sealing - the vessel walls are fused together

In the process of electrosurgical cutting, a high current density is generated by means of electric sparks between the electrode and the tissue. The required electrical power has to be sufficient to heat the tissue up to more than 100 °C in the shortest possible time. This extremely rapid heating process leads to vaporization of the cellular liquid and to cell rupture. Tissue can be separated by movement of the cutting electrode.
In general, larger surface area electrodes of cylindrical or conical form and covering several square millimeters are used for electrocoagulation purposes. Since the contact surface of the electrode is larger and the high-frequency voltage is less than that used during cutting, a lower current density is generated. By this means, the tissue is gradually heated up to the coagulation temperature of approx. 60 °C but it is not vaporized. The aim of the coagulation is either hemostasis by the closure of blood vessels, superficial coagulation or in-depth coagulation, where a volume reduction of excess tissue or large volume destruction of benign or malignant tumors takes place.

2.2 THERMAL INSULT OF COAGULATION AND CUTTING

Each electrosurgical procedure delivers different tissue effects due to different final temperatures of the tissue and the rapidity of tissue heating. Fig. 2.2 shows the thermal insult of methods for coagulation, cutting and vaporization of tissue.

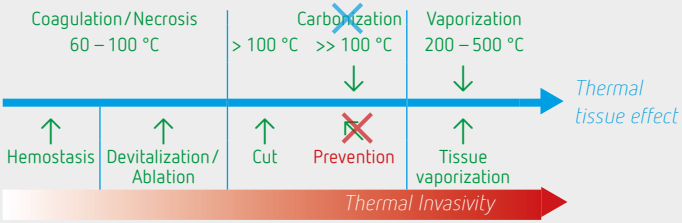

Fig. 2.2 Relation between tissue temperature and tissue effect

2.3 CUTTING AND HEMOSTASIS

Fig. 2.3 shows the influence of electrical power, modulation, contact area and cutting velocity on the cutting quality and hemostasis.

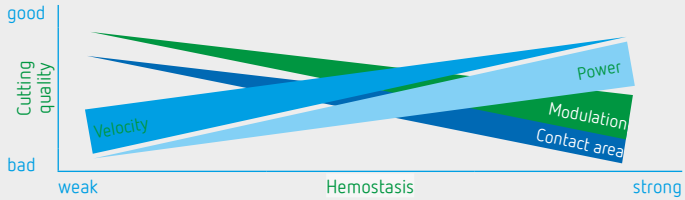

Fig. 2.3 Influence of electrical power, modulation, contact area and cutting velocity on the cutting quality and hemostasis

2.4 COAGULATION

There are many influencing factors with regard to the coagulation effect. The most important factor is the activation time, followed by the electrical power setting. Fig. 2.4 summarizes the most important influencing factors.

Fig. 2.4 Influence of application time, electrical power, contact area / tissue distance and tissue properties on the coagulation effect

APPLICATION TIME

Long activation time → high desiccation level → high tissue damage → risk of carbonization, perforation, lateral damage of adjacent tissue, delayed wound healing

POWER

High power → quick, intense heating → superficial but high tissue damage

CONTACT AREA

Small contact area → high current density → quick, intense heating (e.g. for cutting)

Larger contact area → low current density → slower, weaker heating (e.g. for coagulation)

TISSUE PROPERTIES

Speed and degree of heating depend on the tissue properties, mostly on the electrical tissue resistance.

Coagulation from the electrical point of view

FOR CONSTANT VOLTAGE:

$$\text{power} = \frac{\text{voltage}^2}{\text{resistance}}$$

More resistance denotes less power input into the tissue and thus less heat and less thermal effect (and damage).

FOR CONSTANT CURRENT:

$$\text{power} = \text{current}^2 \times \text{resistance}$$

More resistance denotes more power input into the tissue and thus more heat and more thermal effect (and damage).

HOT SPOTS:

Areas with high current density.

Voltage and current are controlled by the settings of the electrosurgery system (see 3.3). The resistance (impedance) of the tissue is mainly dependent on the water content of the tissue. It is determined by the kind of tissue and the degree of desiccation.

TECHNOLOGICAL ASPECTS

3.1 THE BASICS OF AN ELECTROSURGICAL UNIT (ESU)

In an electrosurgical unit (ESU), line voltage from the power outlet is converted into direct voltage, which is then used to generate the high-frequency alternating voltage, with a peak value of e.g. 200 V, 4000 V or even more. The frequency must exceed 200 kHz to avoid neuromuscular stimulation. This alternating current is then transformed to the desired voltage (200 – 4000 V or even more). Waveform outputs from an electrosurcial unit are shown in Fig. 3.1.

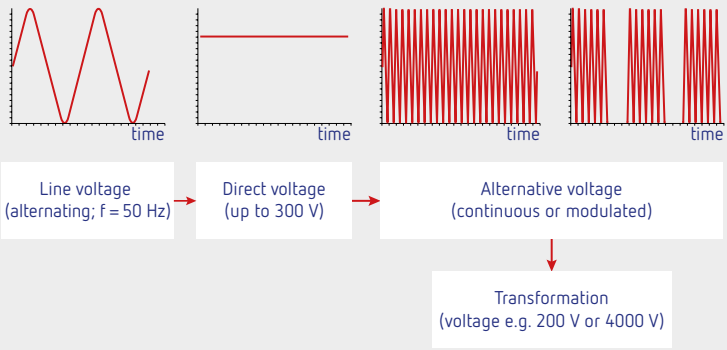

Fig. 3.1 Waveform outputs from an electrosurgical unit (ESU)

Most commonly used ESUs

MANUFACTURER	TYPE
Aesculap B. Braun Melsungen AG	GN640, Nelson® deluxe
BOWA-electronic GmbH & Co. KG	ARC 350
ConMed Corp.	Excalibur PC, System 5000®, 7550™
Erbe Elektromedizin GmbH	ICC 350®, VIO® 300 D
Eschmann	TD830, TD850, TD411RS, E50
KLS Martin	ME MB3, Maxium®
Olympus	SurgMaster® UES40, ESG-100
Covidien-Valleylab	Force Triad®, Force FX®, Force EZ-8C

3.2 CLASSIFICATION OF ELECTROSURGICAL INSTRUMENTS

Electrosurgical instruments are able to work either in a contact or a non-contact manner. Furthermore, due to electrical energy following the "path of least resistance" through the human body, a distinction is drawn between monopolar, bipolar and multipolar application (Fig. 3.2).

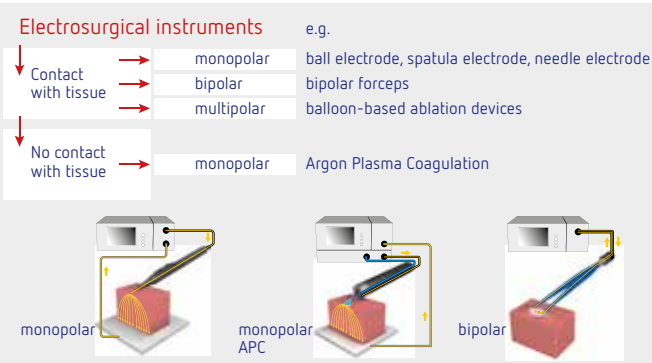

Fig. 3.2 Electrosurgical instruments

3.3 MODES AND REGULATION

VOLTAGE REGULATION
Voltage is kept constant by the electrosurgical device
Reproducible tissue effect for cut and coagulation
Selectivity: tissue effect depends on electrical resistance (tissue type)
Example: muscle tissue can be cut at a lower voltage than fat
SPARK REGULATION
Intensity of sparking is a measure for cutting effect
Constant level of sparking produces reproducible cutting independent of tissue properties
POWER REGULATION
Power is kept constant
Tissue-independent effect
MODULATION
Peak voltage changes with time (alternating high and low voltage, or interruption in brief time intervals)
High peak voltage but low mean power → avoids excessive cutting effect and carbonization
Cutting with coagulated border
Examples for modulated modes: · Power Cut 2,3,4 (Aesculap) · DRY CUT® (Erbe) · ENDO CUT® (Erbe) · Blend (BOWA, ConMed, Eschmann, KLS Martin, Olympus, Covidien-Valleylab)

ELECTROSURGICAL INSTRUMENTS

4.1 OVERVIEW

A	SNARES FOR POLYPECTOMY AND ENDOSCOPIC MUCOSAL RESECTION (EMR)	
B	NEEDLE INSTRUMENTS FOR CUTTING E.G. IN EMR AND ERCP (PRECUT PAPILLOTOMY)	
C	FORCEPS WITH THE ABILITY TO COAGULATE TISSUE	
	monopolar	bipolar
	with window	without window
	with central pin	without central pin
	flat jaws	ridged jaws
	round jaws	oval jaws
D	INSTRUMENTS FOR ENDOSCOPIC SUBMUCOSAL DISSECTION	
	HybridKnife® I-Type, O-Type, T-Type	Erbe Elektromedizin
	ITknife2®	Olympus
	HookKnife™	Olympus
	Triangle Tip Knife	Olympus
	DualKnife®	Olympus
	FlushKnife®	Fujinon
	Splash needle	Pentax
E	INSTRUMENTS FOR ERCP	
	Various papillotomes (standard, precut, Mori knife)	
F	INSTRUMENTS FOR ARGON PLASMA COAGULATION	
	Axial	
	Side fire	
	Circumferential	
G	ABLATION DEVICES	
	Tumor ablation devices (interstitial coagulation)	
	Surface ablation devices (Barrx™)	
	Radio frequency-induced thermotherapy (RFITT)	

4.2 EXAMPLES

A) Snares for polypectomy and endoscopic mucosal resection (EMR)





Fig. 4.1 + Fig. 4.2 Snare for polypectomy and EMR

B) Needle instruments for cutting

Fig. 4.3 Erbe HybridKnife I-Type

C) Forceps with the ability to coagulate tissue

Fig. 4.4 + Fig. 4.5 Forceps

D) Instruments for endoscopic submucosal dissection

Fig. 4.6 Olympus ITknife2®
Fig. 4.7 Olympus HookKnife™

Fig. 4.8 Olympus DualKnife®

Fig. 4.9 Erbe HybridKnife® ↑ O-Type ↓ T-Type

E) Instruments for ERCP



Fig. 4.10 Instrument for ERCP

F) Instruments for Argon Plasma Coagulation

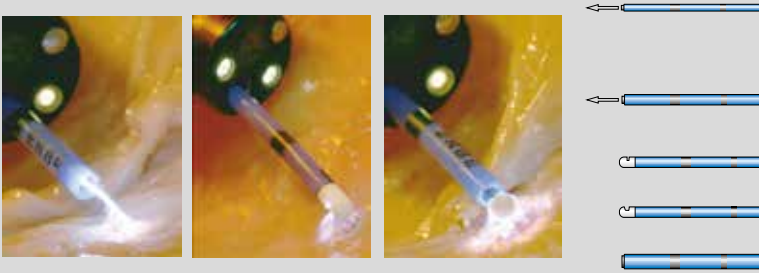

Fig. 4.11 APC probes axial, side fire, circumferential (Erbe)



Fig. 4.12 FiAPC® probe (Erbe)

G) Ablation devices

Fig. 4.13 Radionics Cool-tip®

Fig. 4.14 Boston Scientific Gold Probe™

ELECTROSURGICAL MODES

5.1 CONTINUOUS VS. INTERMITTENT

Modes used in electrosurgery can be continuous (pure modes Fig. 5.1, top) or intermittent (blend modes Fig. 5.1, bottom). The modes are characterized by the peak voltage (Up), the frequency of the alternative current (f > 200 kHz) and the modulation. Higher peak voltage is required for more intensive coagulation. In order to prevent an excessive incision effect and carbonization, the mean power must be decreased. This is achieved by modulating the alternating current, i.e. the current stream is interrupted in brief time intervals (Fig. 5.1, bottom).

Examples (Erbe) for continuous (sinusoidal) pure cut modes:

CUT			
AUTO CUT®	HIGH CUT	PRECISE CUT	BIPOLAR CUT
COAG			
SOFT COAG®	PRECISE COAG	BIPOLAR SOFT COAG	

Examples (Erbe) for intermittent (blend) modes:

CUT			
ENDO CUT®	DRY CUT®		
COAG			
FORCED COAG	SPRAY COAG	SWIFT COAG®	BIPOLAR FORCED COAG

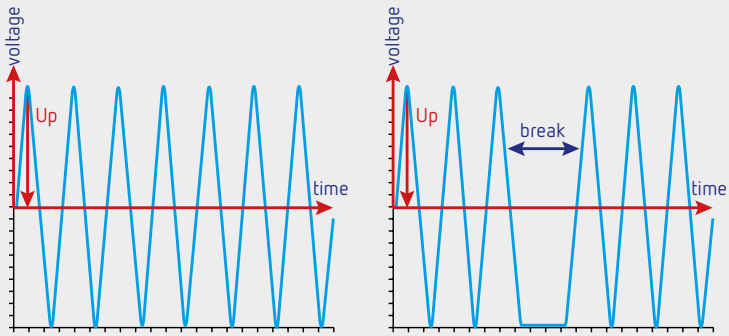

Fig. 5.1 ← Waveform of a continuous mode

→ Waveform of an intermittent (blended) mode

5.2 MANUFACTURER-SPECIFIC TERMINOLOGY

Pure Cut

MANUFACTURER	SPECIFIC TERMINOLOGY
Aesculap B. Braun Melsungen AG	Power Cut 1
ConMed Corp.	Pure Cut
Erbe Elektromedizin GmbH	AUTO CUT® and HIGH CUT
Eschmann	Normal Cut
KLS Martin	Pure Cut
Covidien-Valleylab	Pure Cut and Low Cut

Blended Cut

MANUFACTURER	SPECIFIC TERMINOLOGY
Aesculap B. Braun Melsungen AG	Power Cut 2, 3, 4
ConMed Corp.	Blend 1, 2, 3
Erbe Elektromedizin GmbH	DRY CUT® and ENDO CUT®
Eschmann	Blend
KLS Martin	Blend
Covidien-Valleylab	Blend 1, 2, 3 (Force 2) and Blend (Force FX®)

Contact Coagulation

MANUFACTURER	SPECIFIC TERMINOLOGY
Aesculap B. Braun Melsungen AG	Contact and SOFT COAG®
ConMed Corp.	Pinpoint Coag and Standard Coag
Erbe Elektromedizin GmbH	SOFT COAG® and FORCED COAG
Eschmann	Pinpoint Coag
KLS Martin	Contact Coag
Covidien-Valleylab	Coag and Desiccate Coag

EVERYDAY ELECTROSURGICAL QUESTIONS

6.1 HOW TO GET MORE CUTTING?

Cutting = rupturing of cells due to rapid vaporization of intra-cellular fluid. High current densities are necessary to reach high tissue temperatures.

More cutting by ...

- smaller electrode surface (thin electrodes, monofilament snares instead of polyfilament/braided snares, thin needle knives)
- smaller contact area between electrode surface and tissue
- increased voltage
- reduced velocity of electrode movement, but being too slow also results in more concurrent thermal insult
- increasing cutting period and decreasing coagulation time (this applies for the ENDO CUT® mode)

6.2 HOW TO DECREASE BLEEDING?

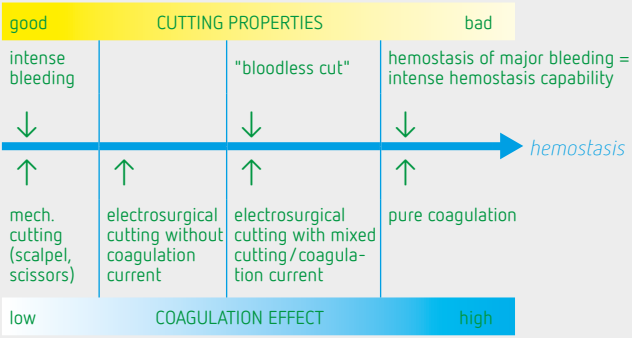

Fig. 6.1 Cutting properties, coagulation effects and the associated hemostasis outcome

Cutting mode with substantial coagulation fraction, such as

- Power Cut 2,3,4 (Aesculap)
- DRY CUT® (Erbe)
- ENDO CUT® (Erbe)
- Blend CUT (BOWA, Covidien, ConMed, KLS Martin, Olympus, Covidien-Valleylab)

leads to less bleeding.

TROUBLESHOOTING

Common problems regarding electrosurgery

PROBLEM: BURN WITHIN OPERATIVE SITE	
HOW TO AVOID?	Check to ensure all non-conductive components are intact.
	Do not exceed the number of cleaning and sterilization steps. Do not clean and sterilize products intended for single use.
	Let the disinfectant dry completely before activating the electrosurgical device.
	Keep flammable substances away from electrosurgical applications.
	Prevent explosive gas mixtures due to oxygen concentrations beyond 40 % during application of argon plasma coagulation in the respiratory tract. Before and during the APC application oxygen must not be directly delivered to the respiratory tract.
	Prevent explosive gas mixtures in the gastrointestinal tract prior to application of electrosurgery. Accordant parts of the bowel must be flushed with water, carbon dioxide (CO_2) or argon to flush away combustible gases like methane and hydrogen. Only use electrosurgery in patients with full bowel preparation.
	Active electrodes should not be deposited on the patient or on combustible material because unintended activation can lead to damage.

Common problems regarding electrosurgery

PROBLEM: BURN BELOW NEUTRAL ELECTRODE / PATIENT PLATE	
HOW TO AVOID?	Application of a split (two or three-part) neutral electrode allowing the control of the contact resistance between electrode and patient. In the case of a partial displacement of the electrode, the application will be stopped.
PROBLEM: INJURY OF THE USER	
HOW TO AVOID?	Prevent unintended contact with the patient during application of electrosurgery, otherwise capacitive currents can lead to tissue burns.

HANDLING OF RETURN ELECTRODES

8. HANDLING OF RETURN ELECTRODES

The return electrode (also referred to as neutral electrode, patient plate or grounding pad) removes current from the patient safely. Return electrodes can heat under certain conditions causing severe tissue burns. A risk of burn can occur if high electrical current is applied over a longer time using an undersized return electrode.

$$\text{burn} \sim \frac{\text{current} \cdot \text{time}}{\text{contact area}}$$

Fig. 8.1 Relation between risk of burn, electrical current, application time and contact area

HANDLING OF RETURN ELECTRODES

To avoid tissue burn, the following recommendations should be considered:

- Use a generator with neutral electrode monitoring technology.
- The return electrode should be as large as possible (only use smaller return electrodes for children if larger return electrodes cannot be placed).
- The placement of the return electrode should be on conductive, well vascularized tissue that is close to the operative site. Avoid locations exhibiting excessive hair, scar tissue, bony structures or other structures suggesting less vascularization.
- Ensure that the return electrode contacts fully with the tissue.
- Use split return electrodes and, optionally, with an equipotential ring (e.g. Erbe NESSY Ω®) whenever possible.

PART II

APPLICATIONS IN GI ENDOSCOPY

BACKGROUND TO ENDOSCOPIC RESECTION (ER)

Endoscopic mucosal resection (EMR) and endoscopic submucosal dissection (ESD) were developed for minimally invasive, organ-sparing endoscopic removal of benign and early malignant lesions in the GI tract. During EMR and ESD, both mucosa and submucosa are removed. EMR is an endoscopic technique developed for the removal of sessile or flat neoplasms confined to the superficial layers (mucosa and submucosa) of the GI tract. EMR is typically used for the removal of lesions smaller than 2 cm or piecemeal removal of larger lesions. The most commonly used techniques are injection, cap and ligation-assisted EMR. Before the start of any EMR technique, it may be helpful to mark the margins of a targeted lesion with superficial cautery marks, except in the colon where margins are easily discernible.
Injection-assisted EMR, also often called "saline-assisted" polypectomy, is frequently used for large flat colon polyps. This technique was introduced in 1955 for rigid sigmoidoscopy and then in 1973 for flexible colonoscopy. The relatively newer technique of ESD allows for en bloc resection of lesions larger than 2 cm in diameter using a dedicated ESD knife. Through this approach, a decrease in the recurrence rate of neoplasia after endoscopic removal can be achieved.

POLYPECTOMY WITH SNARES

9. POLYPECTOMY WITH SNARES

General description

Polypectomy allows endoscopic resection of polyps in the gastrointestinal tract (GI). The lesion is approached under endoscopic view and grasped with the monopolar electrosurgical snare. Dependent upon technique and waveform, activation of monopolar current provides cutting of tissue and coagulation of blood vessels. Neoplastic lesions occur in a broad macroscopic spectrum ranging from small to stalked or large, laterally spread phenotypes (Paris classification type I-type IIc). For the latter, additional injection of fluid to improve complete resection has been recommended. After retrieval, the specimen should be retained for pathologic evaluation.

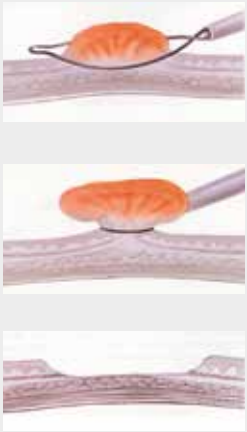

Fig. 9.1 Technique of endoscopic polyp resection with snare
← Schematic view of polyp resection with a snare
→ Endoscopic view of polyp grasped with a monopolar snare

Common settings *(source electrosurgery ENDO CUT®)*

SIZE OF POLYP	< 5 mm	< 10 mm	> 10 mm
METHODOLOGY	Forceps biopsy or cold snare	Cold snaring or snaring with current	Resection with snare
SETTING	N/A	ENDO CUT® Q Effect 2	ENDO CUT® Q* Effect 3 Cutting duration 1 Cutting interval 6

* Additional settings for cutting duration and cutting interval are adjustable in expert mode only

*Specified VIO® effect settings for endoscopic resection in selected GI regions**

EFFECT 1	Cecum, right colon
EFFECT 2	Duodenum, polyps > 5 mm
EFFECT 3	Esophagus, stomach, polyps 5 – 15 mm, rectum, stalked polyps, polyps > 15 mm, large tumors

Workflow

STEP 1	Detection of lesion and characterization
STEP 2	Submucosal injection if necessary
STEP 3	Grasping the lesion
STEP 4	Slight lifting of the lesion towards the lumen
STEP 5	Application of current for cutting and coagulation
STEP 6	Retrieval of specimen

* The chosen effect setting depends on the wall thickness of the GI region.

Pitfalls

EXAMPLES OF INCORRECT POSITIONING OF THE SNARE WITH INCREASED RISK OF PERFORATION

Correct positioning and elevating polyp above intestinal wall			Wrongly positioned snare and damage due to contact of snare with intestinal wall
Controlled grasping prior to elevation in direction of the arrow			Incorrect grasping of polyp with parts of intestinal wall
Increased energy at polyp basis (danger of perforation)			High current at constriction (risk of perforation and bleeding)
Contralateral burns (low risk)			Direct contact with hemo clip

Fig. 9.2 Examples of incorrect positioning of the snare with increased risk of perforation

TIPS AND TRICKS

Proper positioning of the snare around the lesion and use of correct current setting are crucial to provide safe polyp resection. Submucosal injection with various solutions is extremely helpful in preventing deep thermal damage and protecting against perforation.

ENDOSCOPIC MUCOSAL RESECTION (EMR)

10.1 EMR TECHNIQUE OF INJECT-AND-CUT RESECTION

General description

EMR is an established method for resection of gastric, colonic and duodenal lesions. After marking the lesion borders, the procedure starts with the injection of a solution into the submucosal space under the lesion, creating a "safety cushion". The cushion lifts the lesion to facilitate its removal and minimizes mechanical or electrosurgical damage to the deep layers of the GI tract wall. Injection-assisted EMR can be further subdivided into the "inject-and-cut" technique (using an electrosurgical snare through a single-channel endoscope) or the "inject-lift-and-cut" technique (using grasping forceps to lift the lesion and an electrosurgical snare through two separate channels of a double-channel endoscope). The endoscopist benefits from submucosal injection as it provides him with a "lifting sign" for the separation of the lesion from the submucosa and muscularis. The advantages of this method include:

- reduction of the risk of perforation
- prevention of thermal damage to deeper layers
- increased rate of en bloc resection
- easier removal of challenging lesions (large, sessile, behind folds)

ENDOSCOPIC MUCOSAL RESECTION (EMR)

Several options are available for the collection of resected tissue. The method used depends on the size and location of the resected specimens. After cap-EMR, pieces can be sucked into the cap and retrieved directly. After EMR or ESD, the specimens may be collected by specially designed retrieval devices, such as Roth Net® (US Endoscopy), Spider-Net® (ConMed Endoscopic Technologies), or a combination of a polypectomy snare and a retrieval net.

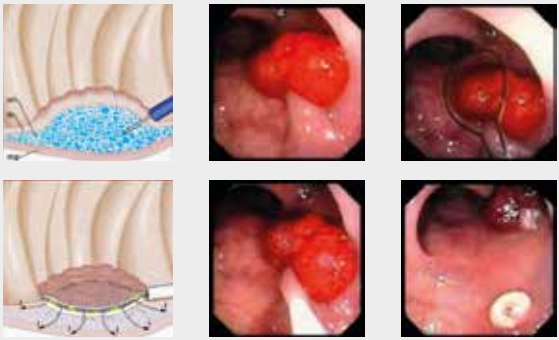

Fig. 10.1 Technique of sequential inject-and-cut snare resection ← Example of inject-and-cut technique with snare resection → Endoscopic view of lesion resection with inject-and-cut technique using needle and snare

Common settings

SUB-STEP OF THE PROCEDURE	MARKING THE LESION (MORE USEFUL IN THE STOMACH)	RESECTION
Setting	FORCED COAG 15–40 W, Effect 1/2	ENDO CUT® Q* Effect 2/3 Cutting duration 1 Cutting interval 3–6
Alternative setting	Or flexible APC probe PULSED APC® 15–25 W, Effect 1	

* Additional settings for cutting duration and cutting interval are adjustable in expert mode only

Specified effect settings for selected GI regions

EFFECT 1	Cecum, right colon
EFFECT 2	Duodenum
EFFECT 3	Stomach, rectum, large tumors

Workflow

STEP 1	Detection of lesion
STEP 2	Marking of the lesion
STEP 3	Injecting solution
STEP 4	Placing the snare
STEP 5	Resection with current
STEP 6	Retrieval of specimen

Pitfalls

- Bleeding
- Perforation

TIPS AND TRICKS

Various solutions are currently used for submucosal injection. The ideal agent should be inexpensive, readily available, non-toxic, non-irritative, easy to inject, and provide a long-lasting submucosal cushion. Normal saline solution is widely available and often used for injection-assisted EMR. However, even with the addition of epinephrine, a cushion made with normal saline solution often dissipates within minutes. Multiple studies have demonstrated long-lasting effects of cushions made with hyaluronic acid and a fibrinogen solution. Hyaluronic acid is expensive and not readily available in most endoscopy units. Common solutions for injecting the submucosa are:

- saline-diluted epinephrine (1:10,000 – 100,000)
- methylene blue / indigo carmine as dye
- "viscous agent" e.g. saline-diluted (hyaluronic acid)

10.2 EMR WITH "SUCK AND CUT" TECHNIQUE FOR FLAT AND DEPRESSED LESIONS

General description

Endoscopic mucosal resection (EMR) is a widely accepted technique for the removal of superficial upper GI lesions. It can either be performed using a transparent cap, which is mounted on the tip of the endoscope (cap-EMR), or a dedicated ligation device (ligation-EMR). Early neoplastic lesions of up to 2 cm in diameter can be resected in one piece (en bloc), whereas larger lesions can be resected by piecemeal-technique using EMR. To improve orientation for complete resections, it is recommended to mark the borders of the target lesion using an electrosurgical needle instrument or APC. Cap-EMR: dedicated snares with a transparent cap are the two main tools for cap-EMR. Cap-assisted EMR uses submucosal injection to lift the target lesion, which makes suction into the cap easier and safer. After suction of the lesion into the cap, a dedicated crescent snare, which perfectly fits the distal inner ring of the cap, is used to grasp the lesion and cut it off. The caps are available in different sizes and shapes (straight or oblique with an outer diameter ranging from 12 to 18 mm) that should be selected according to the lesion size and morphology. Caps are composed of clear plastic that may be soft or hard. The oblique caps are usually used for resection of esophageal lesions (to compensate for the parallel position of the endoscope relative to the esophageal wall), whereas the straight caps are most commonly used in the stomach and colon. The size of the lesion will determine the optimal size of the cap. The largest caps (18 mm) are made from a soft material to allow smooth passage through the narrow portions of the GI tract. Ligation-EMR: a band ligator device (Duette®) is also available to allow sucking and banding of the lesion (with the same concept of variceal ligation) at the base in order to create a pseudopolyp ready to be cut with a snare (quick procedure). Another ligation system is the so-called Euroligator (reusable system). Ligation-EMR does not mandatorily require submucosal injection before resection. The procedure preserves function of the GI tract and allows for precise histological tissue staging. To improve orientation for complete resections it is common to mark the border of the lesion using an electrosurgical needle instrument or APC.

Fig. 10.2 Endoscopic mucosal resection with snare and cap. Images of EMR with the suck-and-cut technique

Endoscopic view of polyp grasped with a cap prior to cutting.

Fig. 10.3 Endoscopic mucosal resection with Duette® system (ligation and cut): image of the resection bed obtained after EMR

Common settings

SUB-STEP OF THE PROCEDURE	Marking the lesion	Resection
SETTING	FORCED COAG 15 – 40 W, Effect 1 / 2	ENDO CUT® Q* Effect 2 / 3 Cutting duration 1 Cutting interval 3 – 6
ALTERNATIVE SETTING	Or flexible APC probe PULSED APC® 15 – 25 W, Effect 1	

* Additional settings for cutting duration and cutting interval are adjustable in expert mode only

Workflow

STEP 1	Detection of lesion and marking of the borders
STEP 2	Submucosal injection if necessary (saline, dye, epinephrine)
STEP 3	Positioning the transparent cap and sucking in the mucosa to retract the lesion from surface (release the band in the case of Duette® technique)
STEP 4	Placing the snare around the polyp
STEP 5	Resection with electrosurgical current
STEP 6	Retrieval of specimen for evaluation

Pitfalls

- Bleeding
- Perforation

TIPS AND TRICKS

Dyes for visualization of the lesion:

- Conventional chromoendoscopy using indigo carmine / acetic acid / methylen blue for early Barrett's neoplasia or gastric lesions, lugol for esophageal squamous cell neoplasia.
- Virtual chromoendoscopy (NBI, FICE, i-scan depending on the endoscope available).

Proper injection of the submucosa, complete retraction of the lesion into the cap, full closure of the snare during grasping. Appropriate setting of the ESU (ENDO CUT®).

10.3 CSI-EMR (CIRCUMFERENTIAL SUBMUCOSAL INCISION PRIOR TO EMR)

General description

This combination technique may be adopted to obtain en bloc resection of large lesions. The neoplastic lesion is isolated by a circumferential mucosal incision prior to endoscopic mucosal resection (EMR) using ESD knives, needle knives or the distal tip/nose of the snare.
After marking resection margins (not required for colonic lesions) using small dots of coagulation, submucosal injection is performed throughout the surface of the lesion. Subsequently, a needle knife or a hook knife together with ENDO CUT® Q can be employed for circumferential incision of the mucosa around the lesion. A snare is then placed in the incision groove and grasped to include the entire lesion for final en bloc resection. If a double channel endoscope is available, a second grasper can be used to lift up the central part of the lesion.

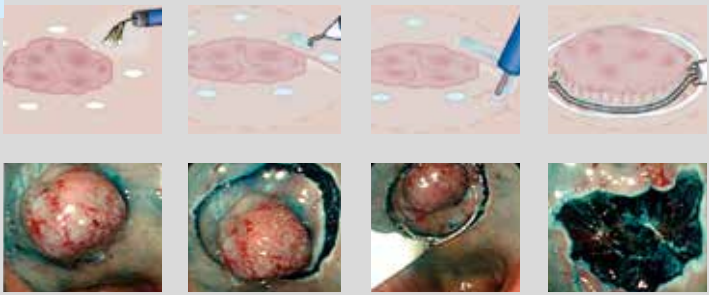

Fig. 10.4 Technique of EMR with circumferential submucosal incision ↑ Lesion marking and slitting with a needle instrument prior to snare resection ↓ Circumferential EMR

Common settings

SUB-STEP OF THE PROCEDURE	Marking the lesion	Mucosal incision and resection
SETTING	FORCED COAG 15 – 60 W, Effect 1 / 2	ENDO CUT® Q* Effect 2 Cutting duration 4 Cutting interval 3
ALTERNATIVE SETTING	Or flexible APC probe PULSED APC® 15 – 25 W, Effect 1	

* Additional settings for cutting duration and cutting interval are adjustable in expert mode only

Workflow

STEP 1	Detection of lesion
STEP 2	Marking of the lesion (if gastric or esophageal)
STEP 3	Injecting solution
STEP 4	Slitting lesion with needle knife, hook knife or snare itself
STEP 5	Placing the snare around the lesion
STEP 6	Resection with electrosurgical current in a standard manner
STEP 7	Retrieval of specimen

Pitfalls

Due to the higher risk of perforation, this EMR technique is most commonly carried out in tertiary level centers by physicians with proved expertise in endoscopic resection techniques.

TIPS AND TRICKS

The use of a distal attachment cap for submucosal incision is extremely helpful and makes the procedure quicker. For circumferential cutting with an electrosurgical knife use ENDO CUT® Q; for submucosal dissection with a snare also use ENDO CUT® Q.

ENDOSCOPIC SUBMUCOSAL DISSECTION (ESD)

11.1 ESD WITH COMBINATION AND MULTIFUNCTION INSTRUMENTS (HYBRIDKNIFE®)

General description

The Erbe HybridKnife® is an innovative device developed specifically for ESD procedures that combines an ultrafine high-pressure waterjet with an electrosurgical needle. This flexible device allows submucosal injection with a preselected pressure through a standard working channel. Furthermore, the device is used for marking of the targeted lesion, circumferential cutting, submucosal dissection and coagulation, as well as cutting, blunt preparation, rinsing of blood clots, and rinsing for a better endoscopic view by waterjet application. It is the only available device that allows the performance of the entire ESD procedure without exchanging multiple devices with different functions. It has already been tested in both animal and human studies with excellent outcomes.

Fig. 11.1 ESD with HybridKnife®
←ESD working steps using the Erbe HybridKnife®
→Endoscopic view of the incision/dissection step with the Erbe HybridKnife®

Common settings

FOR ALL SELECTED TISSUE TYPES PULSED APC® 20 W OR FORCED COAG EFFECT 1, 20 W OR SOFT COAG EFFECT 5, 80 W			
LOCATION	MUCOSAL ELEVATION (BAR)	INCISION/ DISSECTION	COAG-ULATION
Esophagus	Effect 30 – 50	ENDO CUT® Q* Effect 2/3 Cutting duration 3 Cutting interval 3 DRY CUT® 80 W, Effect 2 (higher degree of hemostasis)	FORCED COAG Effect 2 50 W
Stomach	Effect 30 – 50	See above	See above
Right colon	Effect 10 – 15	See above	See above
Rectum, left colon	Effect 20 – 30	See above	See above

* Additional settings for cutting duration and cutting interval are adjustable in expert mode only

ENDOSCOPIC SUBMUCOSAL DISSECTION (ESD)

Workflow

STEP 1	Marking of lesion margins with coagulation points
STEP 2	Elevation of mucosa by waterjet infiltration
STEP 3	Circular incision and dissection of the submucosa with different settings related to different locations
STEP 4	Coagulation of blood vessels after resection with FORCED or SOFT COAG
STEP 5	Retrieval of specimen

Pitfalls

- Bleeding
- Perforation

TIPS AND TRICKS

Due to the fluid cushion in the submucosa, the risk of perforation may be significantly reduced compared to traditional ESD procedures. The use of one device combining the injection and cutting functions may lead to a shorter procedure time.

11.2 ESD WITH CONVENTIONAL KNIVES

General description

ESD has been developed for en bloc removal of large (usually more than 2 cm), flat GI tract lesions. The procedure is usually done in several steps. First, the margins of the lesion are marked electrosurgically (especially gastric and esophageal) and a submucosal injection is used to lift the lesion. Then, a circumferential incision into the submucosa is performed around the lesion with specialized endoscopic electrosurgical knives. Finally, the lesion is dissected from underlying deep layers of GI tract wall using electrosurgical knives and is subsequently removed. After removal, the en bloc pathologic specimen should be fixed to cork or other similar materials and oriented to facilitate histologic examination. Multiple cutting devices and accessories have been developed specifically for ESD. En bloc resection provides precise histological assessment of the resected specimen. For visualization and discrimination of lesions from healthy tissue prior to intervention, chromoendoscopic dyes, e.g. methylene blue or indigo carmine, are applied. Submucosal injection of fluid provides a fluid cushion that separates the mucosa layer from submucosa. An electrosurgical knife, e.g. Hybrid-Knife, ITknife or HookKnife, is first used to incise the mucosa and then the submucosal tissue until complete lesion removal is achieved. A careful hemostasis of submucosal vessels is required to obtain optimal visibility. A device specifically devoted to hemostasis (hot forceps or Coagrasper®) may be required to seal large submucosal vessels prior to transection and/or to control active bleeding during the procedure.

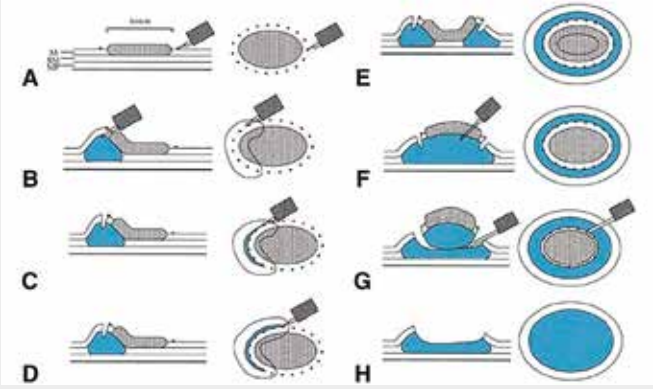

Fig. 11.2 ESD of an early gastric cancer lesion visualized with indigo carmine solution
Illustration of sequential ESD procedure with a needle knife

Endoscopic view of native early gastric cancer lesion and selected resection steps

Common starting settings for selected Olympus ESD knives

ERBE ICC 200®

NEEDLE KNIFE	
Incision	**AUTO CUT®** 120 W, Effect 3 **ENDO CUT®** 120 W, Effect 3
Dissection	**ENDO CUT® Q** Effect 2 / 3 **DRY CUT®** 50 W, Effect 2 / 3
Hemostasis	**FORCED COAG** 50 W
IT KNIFE	
Incision	**ENDO CUT®** 60, 80 or 120 W, Effect 3 **AUTO CUT®** 120 W, Effect 3
Dissection	**ENDO CUT®** 80 W, Effect 3 or 120 W, Effect 3
Hemostasis	**ENDO CUT®** 120 W, Effect 3 **FORCED COAG** 40 W **SOFT COAG®** 50 W
HOOK KNIFE	
Incision	**ENDO CUT®** 60 W, Effect 3 **AUTO CUT®** 60 W, Effect 3
Dissection	**FORCED COAG** 60 W
Hemostasis	**FORCED APC / PULSED APC** 60 W
TRIANGLE TIP KNIFE	
Incision	**ENDO CUT®** 120 W, Effect 3 **AUTO CUT®** 120 W, Effect 3
Dissection	**FORCED COAG** 60 W
Hemostasis	**FORCED COAG** 60 W

ERBE VIO® 300 D

IT KNIFE	
Incision	**ENDO CUT® I** Effect 2, cutting duration 3, cutting interval 1 **DRY CUT®** 50 W, Effect 4
Dissection	**ENDO CUT® I** Effect 2, cutting duration 3, cutting interval 1 **DRY CUT®** 50 W, Effect 2 – 4
Hemostasis	**SWIFT COAG®** 50 W, Effect 4
HOOK KNIFE	
Incision	**DRY CUT®** 60 W, Effect 2 / 3
Dissection	**DRY CUT®** 60 W, Effect 3 **FORCED COAG** 50 W, Effect 2
Hemostasis	**FORCED COAG** 50 W, Effect 2 **SPRAY COAG** 50 W, Effect 2
DUAL KNIFE	
Incision	**DRY CUT®** 30 W, Effect 2 / 3
Dissection	**SWIFT COAG®** 30 / 40 W, Effect 4
Hemostasis	**SWIFT COAG®** 30 / 40 W, Effect 4

Workflow

STEP 1	Identification and demarcation of lesion by chromoendoscopy
STEP 2	Marking of lesion with electrosurgery using e.g. needle knife
STEP 3	Submucosal injection to lift mucosa
STEP 4	Circumferential incision of lesion with knife
STEP 5	Submucosal dissection
STEP 6	Grasping and retrieval of resected specimen from lumen

Pitfalls

- Perforation
- Bleeding
- Incomplete resection

TIPS AND TRICKS

Proper submucosal injection with dedicated fluids, use of a distal attachment cap (transluminal ESD cap) on the tip of the scope, and careful hemostasis of all visible vessels in the submucosa to prevent diffuse bleeding, which hinders the endoscopy view. Optimal settings based upon the instrument and technique.

PAPILLOTOMY / SPHINCTEROTOMY

General description

Endoscopic biliary papillotomy has almost completely replaced surgery for bile duct access. The term sphincterotomy refers to the incision of the papilla of Vater containing the sphincter of Oddi. It allows for stone extraction, tissue biopsy or brushing, stent placement and stricture dilatation. The approach involves insertion of a papillotome into the bile duct and subsequent incision of the papilla duodenum major using electrosurgery. Gaining access to the biliary system via the major papilla is a critical step in the intervention. The overall success rate for cannulation of the papilla is in the range of 90 to 95 %. A small percentage of attempts to enter biliary systems fails, even in the hands of expert endoscopists. In these cases, precut sphincterotomy, also described as "access sphincterotomy", is an option to obtain deep cannulation of the bile duct. Different types of papillotomes are used nowadays either for standard or precut sphincterotomy.

Fig. 12.1 Papillotomy in an endoscopic setting ← Cannulation of the papilla ↑ Incision of the major papilla → Coagulation with alternating cutting / coagulation cycles according to ENDO CUT® I mode

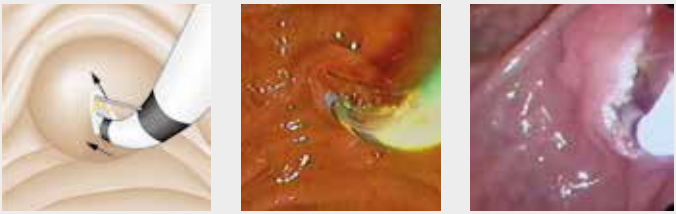

Fig. 12.2 Endoscopic view of papilla major incision using ENDO CUT® ← Schematic view → Endoscopic view

Common settings (based upon published data)

- Alternating cutting and coagulation:
  ENDO CUT® I Effect 2
- Standard guide-wire sphincterotomy:
  ENDO CUT® I Effect 2
  FORCED COAG 50 W, Effect 2
  Alternatively **SOFT COAG®** 80 W, Effect 5 for hemostasis only as needed
- Pre-cut sphincterotomy with needle knife:
  ENDO CUT® Effect 2 (or Effect 1 without coagulation)
  FORCED COAG 50 W, Effect 2

Workflow

STEP 1	Endoscopic targeting and probing the major papilla using the papillotome and guide wire
STEP 2	Deep cannulation of the duct with papillotome / sphincterotome
STEP 3	Orientation of papillotome current wire in cutting direction
STEP 4	Incision of papilla by electrosurgical current activation
STEP 5	Application of specific procedures for stone extraction, stent placement or stricture dilatation

Pitfalls

- "Zipper Cut": short and uncontrolled cutting, meaning not enough time for coagulation, thus increasing the risk of bleeding and perforation!
- Incomplete sphincterotomy.
- Losing the anatomy and access to the orifice, especially in needle-knife EPT.

TIPS AND TRICKS

- The preferable cutting direction for biliary sphincterotomy is between the 11 o'clock and 1 o'clock positions.
- Continuous activation of ENDO CUT® for the whole EPT (no "zipper").
- Always use ENDO CUT Effect 2.

12.1 PANCREATIC STANDARD AND NEEDLE-KNIFE SPHINCTEROTOMY

General description

As for the biliary system, ERCP also allows access to the pancreatic duct for the management of stones, strictures and leaks. Pancreatic cannulation and subsequent sphincterotomy is performed using the same devices for biliary cannulation but with changed anatomic orientation of the devices. When using a pull-type sphincterotome, a guide wire is advanced into the pancreatic duct and electrosurgical current is applied to cut the papilla at a length between 5 and 10 mm. Using needle knives requires placement of a pancreatic duct stent prior to intervention to obtain a cutting plane for the knife. Thus a cut of 5 to 10 mm is directed along the longitudinal axis of the stent to incise the papilla.

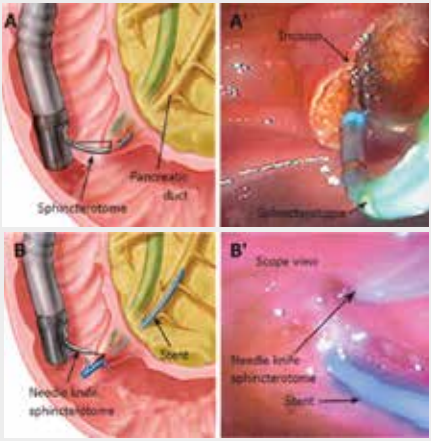

Fig. 12.3 Pull-type and needle-knife sphincterotomy
↑ Pancreatic sphincterotomy performed with pull-type sphincterotome ↓ Pancreatic sphincterotomy performed with needle knife over a pancreatic stent

Common settings (based upon published data)

METHOD	Needle-knife sphincterotome and pull-type sphincterotome
CURRENT MODE	Alternating cutting and coagulation: ENDO CUT® I
SELECTED SETTINGS	ENDO CUT® Effect 2 FORCED COAG 50 W, Effect 2 Alternatively SOFT COAG® 80 W, Effect 5

Workflow

STEP 1	Endoscopic targeting and probing the major papilla using the papillotome
STEP 2	Deep cannulation of the duct with papillotome / sphincterotome
STEP 3	Orientation of papillotome current wire in cutting direction
STEP 4	Incision of papilla by electrosurgical current activation
STEP 5	Application of specific procedures for stone extraction, stent placement or stricture dilatation

Pitfalls

- The length of the cut should be shorter compared with standard biliary sphincterotomy.
- Slight rotation of the sphincterotome on the right may facilitate pancreatic duct cannulation and cut of the papilla.

TIPS AND TRICKS

- Cutting direction with the needle knife is directed between the 10 and 11 o'clock positions.
- Cutting direction with the pull-type sphincterotome is carried out in the direction of the 1 to 2 o'clock positions.

12.2 PRECUT PAPILLOTOMY / SPHINCTEROTOMY

General description

Precut papillotomy (or sphincterotomy) refers to a variety of endoscopic techniques used to facilitate selective bile duct access during endoscopic retrograde cholangiopancreatography (ERCP) in patients in whom conventional cannulation has failed. There are several techniques to perform precut papillotomy with the most widely practiced approach being the free-hand needle-knife, in which an incision is made starting at the orifice and extending proximally for a variable distance according to the papilla anatomy and underlying disease. However, precut papillotomy is associated with a higher complication rate and does not always facilitate successful initial cannulation. If biliary cannulation is not successful immediately after precut papillotomy, many endoscopists prefer to repeat the ERCP after an interval to allow papillary edema to improve.

Common settings (based upon published data)

METHOD	Needle-knife sphincterotome or short-nose standard precut sphincterotome
CURRENT MODE	Alternating cutting and coagulation: ENDO CUT® I
SELECTED SETTINGS	ENDO CUT® Effect 2 FORCED COAG 50 W, Effect 2 Alternatively SOFT COAG® 80 W, Effect 5 for hemostasis only

Workflow

STEP 1	Place duodenoscope in a shorter position to facilitate control of movements
STEP 2	Perform phantom movements with the needle out (in the direction of anticipated cut)
STEP 3	Start cutting the mucosal layer in the biliary direction
STEP 4	Incise in the deeper layer to open the biliary side of the papillary orifice
STEP 5	Gently advance the device inside the fistula to get deep access to the biliary duct
STEP 6	If deep cannulation is obtained, advance a guide wire into the precut catheter

Pitfalls

- The length of the cut changes according to papilla morphology.
- The direction of the cut is similar to biliary sphincterotomy. Sometimes placement of a pancreatic stent can be used to assist the cut and prevent post-procedural pancreatitis. The risk of complication is slightly increased as compared with standard biliary sphincterotomy.

TIPS AND TRICKS

In difficult positions, the needle knife tip can be bent slightly upward to create tension on the tissue for an efficient cut. Small papillae may require a cut starting from the orifice. Larger, bulging papillae are cut easier with an incision at the top of the bulging area. If bile comes out from the cut, advancement of a guide wire deep in the bile duct may facilitate cannulation.

THERMAL HEMOSTASIS

13.1 HEATPROBE™ (OLYMPUS)

General description

The HeatProbe™ for thermal hemostasis consists of a Teflon-coated hollow cylinder containing a heating coil. It allows for the coagulation of tissue without any electrical current flow throughout the patient's body (bipolar current). Additionally, the source of bleeding is compressed by the probe ("coaptive coagulation"). Newer catheters have an injector needle incorporated, which enables combination therapy (injection plus thermal). The HeatProbe™ is used for upper GI bleeding, mainly ulcer bleeding. There is a lack of data for lower GI bleeding.

Fig. 13.1 HeatProbe™ (Olympus)

THERMAL HEMOSTASIS

Recommended settings

BLEEDING	Upper gastrointestinal bleeding / ulcer bleeding
POWER SETTING	30 J

Workflow

STEP 1	Generous irrigation to identify the bleeding lesion
STEP 2	Suction of blood so that the vessel stump can be seen
STEP 3	Gently place the HeatProbe™ on the bleeding vessel stump and compress it
STEP 4	Application of heat (ca. 200 °C) for a short time (5 – 10 seconds)
STEP 5	After hemostasis, remove the probe carefully without causing rebleeding by tissue sticking

Pitfalls

- Tissue can stick at the distal end of the probe and may cause rebleeding after removal.
- Deeper penetration in the organ wall compared with argon plasma coagulation.

TIPS AND TRICKS

The HeatProbe™ is recommended for the following indications:

- Bleeding peptic ulcers
- Dieulafoy's ulcer
- Mallory-Weiss lesions

Combination therapy (injection plus burning of the vessel) is the most effective approach, according to most clinical trials.

13.2 FORCEPS

General description

Monopolar hemostasis forceps are used to stop bleeding from larger vessels (> 2 mm) or to preventively coagulate exposed vessels with a risk of bleeding during an endoscopic procedure. The main field of application is hemostasis during endoscopic resections like endoscopic mucosal resection (EMR) or endoscopic submucosal dissection (ESD). Nowadays, there are also bipolar coagulation forceps available.

Fig. 13.2 Coagrasper® Electrosurgical Hemostatic Forceps (Olympus)

Recommended settings

APPLICATION	Bleeding during EMR / ESD / polypectomy
MODE	SOFT COAG®
SETTING	80 W, Effect 5

Workflow

STEP 1	Grasp the bleeding lesion or the visible vessel
STEP 2	Gently pull back the vessel to avoid transmission of current in the deeper layers of the GI wall
STEP 3	Facilitate coagulation until the bleeding is stopped or exposed vessels look whitish or chalky
STEP 4	Release the forceps carefully to prevent rebleeding due to tissue sticking

Pitfalls

- Tissue can stick at the distal end of the probe and may cause rebleeding after removal especially using FORCED COAG modes.
- Deeper penetration in the organ wall for longer application times compared with APC.
- Dedicated devices for gastric or colonic vessels should be used according to the site of endoscopic operations.

TIPS AND TRICKS

- Hemostasis forceps are recommended for vessels > 2 mm or active bleeding not controllable with standard surgical devices.
- Recommended for endoscopic resections, especially for ESD.
- Longer application times result in deeper tissue effect at low carbonization of the tissue surface.
- No micro-electric sparks occur.
- Low tissue sticking using SOFT COAG® mode.
- In case of active bleeding, forced water lavage is recommended to properly identify the target vessel. Alternatively, a preventive adrenaline injection can help in reducing the flow of bleeding and improve the coagulation effect.

ARGON PLASMA COAGULATION (APC)

14.1 COAGULATION OF TUMORS – APC

General description

Utilizing a monopolar circuit, APC causes tissue coagulation, desiccation and destruction via the transfer of energy from the APC probe to the tissue in the form of ionized, electrically conductive argon gas ("plasma"). The APC probe produces a plasma spark that can destroy tissue to a depth of approximately 4 to 5 mm. Successful APC use has been reported in peer reviewed papers demonstrating its value in coagulation of diffuse bleeding, such as angiodysplasia, GAVE syndrome, radiation proctitis and bleeding ulcers. Tissue ablation of large tumor masses (debulking) can be achieved with APC by using higher power settings with longer activation times as deemed appropriate. As a consequence, most of the tissue treated by APC is thermally necrosed. Besides the direct removal of large tumor masses, thermally necrotized tissue dies off in the subsequent postoperative days. The combination of tissue vaporization and late necrosis produces a substantial mass reduction with significant clinical benefits in the majority of cases.

Fig. 14.1 ↖ Extensive duodenal adenoma before APC treatment
Fig. 14.2 ↗ Extensive duodenal adenoma after APC treatment

Common settings

TUMOR SIZE	Large (> 15 mm)	Small (< 15 mm)
MODE	FORCED APC®	FORCED APC®
SETTING	> 60 W	20 – 50 W

Workflow

STEP 1	Start on distal portion
STEP 2	Frequent movement of the APC probe until most of the tumor mass is thermally insulted

Pitfalls

- Colon: risk of colon explosion if methane and/or hydrogen gas is present. Careful bowel preparation is necessary.
- Diffusion of argon gas leading to submucosal emphysema. This can be avoided by keeping direct tissue contact of the APC probe to a minimum and by using as low an argon flow as possible.
- Perforation (do not apply too long over the same anatomic location).

TIPS AND TRICKS

- Start with the common setting and raise the power setting incrementally, if necessary.
- Always work under visual control.
- Activate the APC probe during retraction.
- Avoid direct tissue contact.
- Do not press the APC probe into the tissue.
- Avoid sparking near metal clips/metal instruments.
- Use repeated gas suction to avoid bowel distension.

14.2 COAGULATION OF RESIDUAL TISSUE POST-POLYPECTOMY WITH APC

General description

After polypectomy and endoscopic mucosal resection (EMR) using snares in a piecemeal fashion, tiny residual adenoma are common. An effective, safe and inexpensive method for ablation of residual adenoma is post-treatment with APC. In published studies, significant reduction of adenoma recurrence after APC treatment is reported.

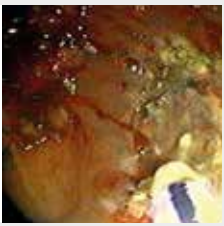

Fig. 14.3 ↖ Adenoma in the cecum
Fig. 14.4 ↗ Injection of adenoma
Fig. 14.5 ↙ Snaring of adenoma (piecemeal)
Fig. 14.6 ↘ Ablation of bed with APC

Common settings

PREVIOUS SURGICAL PROCEDURE	Incomplete polypectomy	Incomplete EMR
MODE	PULSED APC® Effect 1/2	PULSED APC® Effect 1/2
SETTING	20 – 30 W	20 – 30 W

Workflow

STEP 1	Completion of polypectomy or EMR
STEP 2	Precise repeated application of the APC probe on the border of the resection site until visible residual adenoma is ablated

Pitfalls

- Colon: risk of colon explosion if methane and/or hydrogen gas is present. A careful bowel preparation is necessary.
- A careful application of APC can also be useful to coagulate exposed vessels on the ground of polyp resection.
- Burning of adenomatous tissue left behind can be assisted by any form of electronic chromoendoscopy (NBI, i-scan, FICE), which can better identify the target tissue to be eradicated.

TIPS AND TRICKS

- Start with APC ablation after having removed all the fragments of the polyp.
- Keep the probe stationary and gently move the scope to obtain very precise burning of small adenomatous areas.
- Provide APC coagulation of the entire circumference of the resection area even when the margins seem to be clear.

14.3 CHRONIC BLEEDING: RADIATION PROCTITIS – APC

General description

Irradiation of tumors located in the abdomen or in the pelvis (prostate, ovary) as well as in the gastrointestinal tract bears the risk of developing patchy mucosal vascular lesions, which are associated with an increased risk of chronic bleeding and subsequent anemia. These bleeding lesions are more frequent in the rectum and can be successfully treated with APC.

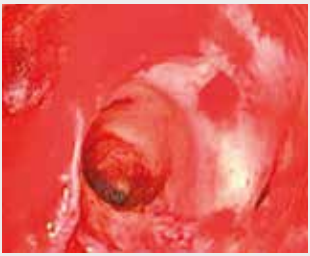

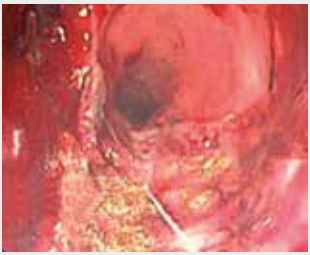

Fig. 14.7 ↑ Extensive bleeding after irradiation

Fig. 14.8 ↓ Hemostasis of bleeding with APC after irradiation treatment

ARGON PLASMA COAGULATION (APC)

Common settings

MODE	PULSED APC®, Effect 2
SETTING	10 – 30 W
NUMBER OF SESSIONS	2 – 3 (interval of 3 to 4 weeks)

Workflow

STEP 1	Start on distal portion and move proximally
STEP 2	Place the probe precisely on the tiny vascular lesion
STEP 3	Apply APC and repeat until most of the lesions are coagulated. Paint the treatment area moving the scope with the proper technique

Pitfalls

- Colon: risk of colon explosion if methane and/or hydrogen gas is present. Careful bowel preparation is necessary.
- Active bleeding after APC when on anticoagulants.
- Multiple sessions at 3 to 4-week intervals are required.
- Sometimes a post-procedural increase of blood loss is reported after the first session.

TIPS AND TRICKS

- Adequate sedation is necessary if the lesion is very close to the anal verge. Consider the application of local anesthetics.
- Technique – short activation times, constant movement.
- Stool softeners are suggested to reduce mechanical trauma due to post-procedural fecal passage.

14.4 CHRONIC BLEEDING: GAVE – APC

General description

GAVE (gastric antral vascular ectasia), also called watermelon stomach, is a cause of chronic gastrointestinal bleeding. Most of the patients with GAVE have a history of hepatic or renal diseases. It is associated with superficial, dilated small blood vessels exposed at the mucosal layer mainly in the antrum, resulting in chronic bleeding. Diffuse characteristic stripes of the lesions can be observed, mimicking a watermelon-like aspect.

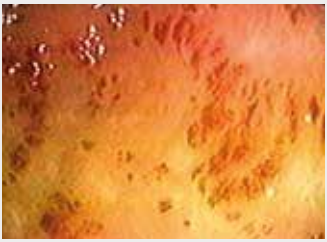

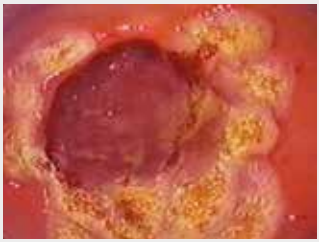

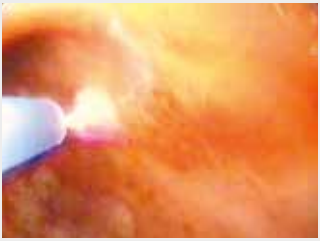

Fig. 14.9 ↖ Characteristic stripes of diffuse bleeders
Fig. 14.10 ↗ APC "paints" large areas with surface fibrin after APC treatment
Fig. 14.11 ↓ Superficial coverage with little charring after APC treatment

ARGON PLASMA COAGULATION (APC)

Common settings

MODE	PULSED APC® Effect 2
SETTING	10 – 30 W

Workflow

STEP 1	Start on the greater curvature in the more distal position
STEP 2	Backwards, slow movement of the APC probe along the characteristic stripes
STEP 3	Repeat the same operation 2 to 3 times along the same stripes to reach more effective vessel coagulation

Pitfalls

- Long procedures require a dedicated sedation protocol.
- Check INR and platelet value before starting endoscopy.
- Clear the mucosal surface from mucus and gastric debris before starting APC coagulation.
- Routinely aspirate the stomach to avoid excessive gastric distension.
- Several sessions at 2 to 3-week intervals are generally required.

TIPS AND TRICKS

- Use of therapeutic channel scope to make gas and air aspiration easier during the procedure.
- Keep the catheter short to maximize the field of view and use an endoscope, not the catheter for APC application.
- Combination of APC treatment with proton pump inhibitor therapy and sucralfate to accelerate mucosal healing.

14.5 ACUTE BLEEDING: BLEEDING ULCERS – APC

General description

Gastroduodenal ulcers can be complicated by acute bleeding secondary to the erosion of submucosal vessels.
A number of prospective clinical studies have shown that APC alone or in combination with injection therapy can safely and effectively be used in the treatment of bleeding peptic ulcers. APC is most suitable for the management of patients with Forrest Ib, IIa or IIb stigmata of bleeding. It is well-known and evidence-based that a combination therapy of APC and injection is more effective than a single therapy alone.

Fig. 14.12 Ablation of a visible vessel

Common settings

FORREST CLASSIFICATION	MODE	SETTING
Forrest Ib	FORCED APC®	30 – 60 W
Forrest IIa	FORCED APC®	30 – 60 W
Forrest IIb	FORCED APC®	20 – 40 W

ARGON PLASMA COAGULATION (APC)

Workflow

STEP 1	Inject diluted epinephrine at four quadrants around the bleeding ulcer
STEP 2	Address the APC probe toward the stigmata and then release short bursts of coagulation
STEP 3	Repeat several times until active bleeding stops or a nice, slightly depressed coagulation area takes the place of the target vessel

Pitfalls

- Keep the probe very close to the vessel to obtain hemostasis of the deeper part of the exposed vessel.
- Avoid prolonged coagulation attempts if active bleeding cannot be stopped and endoscopic vision gets worse.
- Combine aggressive water flush and coagulation to maintain a very clean endoscopic view.
- If required, repeat the 4-quadrants injection before proceeding with a second round of coagulation.
- Proton pump inhibitors (PPI) is recommended after endoscopic therapy.

TIPS AND TRICKS

Ulcers of the posterior duodenal wall can have a larger bleeding vessel and thus a more aggressive therapy may be required. In the case of Forrest IIc, inject first and snare off the big clot above the ulcer ground and be ready to provide APC energy immediately afterwards.

14.6 ACUTE BLEEDING: NON-VARICEAL BLEEDING – APC

General description

The major cause of upper non-variceal bleeding is peptic ulcers. Other causes are mucosal tears of the esophagus or fundus, erosive gastritis, erosive esophagitis, Dieulafoy's lesion and ulcerated gastric submucosal lesions.

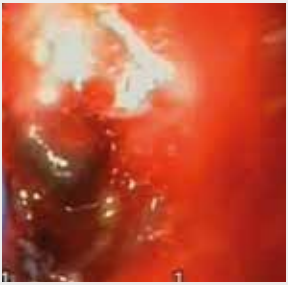

Fig. 14.13 ← Forrest IIa bleeding
Fig. 14.14 → Forrest IIb bleeding

Common settings

BLEEDING SOURCE	MODE	SETTING
Dieulafoy's ulcer	FORCED APC®	30 – 60 W
Tumor bleeding	FORCED APC®	30 – 60 W
Erosions	PULSED APC®	20 – 40 W
Mallory-Weiss	PULSED APC®	20 – 40 W

ARGON PLASMA COAGULATION (APC)

Workflow

STEP 1	Start on distal portion
STEP 2	Address the APC probe toward the stigmata and then release short bursts of coagulation
STEP 3	Repeat several times until active bleeding stops or a nice, slightly depressed coagulation area takes the place of the target vessel

Pitfalls

- Most of these bleeding lesions may require combination therapy (injection plus APC). However, when the bleeding source is tiny or has already stopped, just APC can be applied.
- In the case of multiple bleeding lesions, carefully deliver the APC treatment to all the lesions.
- IV PPI is recommended after endoscopic treatment.

TIPS AND TRICKS

- In the case of torrential bleeding, use a naso gastric tube to evacuate fresh blood and clots.
- If the bleeding source is not identified, rotate the patient on his back to move the clots inside the stomach.
- In the case of Dieulafoy's lesion, apply longer bursts of APC since the bleeding vessel is usually larger and originating from the deeper part of the gastric wall.

14.7 STENT INGROWTH / OVERGROWTH OF TUMOR TISSUE – APC

General description

In the case of uncovered metallic stents, neoplastic or hyperplastic tissue can proliferate inside the metallic meshes leading to stent obstruction. The same complication can happen above or below the stent ends. This is called stent ingrowth / overgrowth. The removal of tumor ingrowth / overgrowth or hyperplastic tissue can be managed successfully with APC treatment.

Fig. 14.15 ← Ingrown stent in esophagus before APC treatment
→ Stent in esophagus after APC treatment

Common settings

MODE	SETTING
FORCED APC®	20 – 40 W
Alternative PULSED APC® Effect 2	40 – 60 W

ARGON PLASMA COAGULATION (APC)

Workflow

STEP 1	Start in proximal position
STEP 2	Burn the tissue in a circumferential manner or use circumferential APC probe
STEP 3	Proceed by advancing the scope in the obstructed stent until it is completely reopened

Pitfalls

- Risk of destruction or melting of the stent if the power setting is too high or the probe is activated in contact with the mesh.
- Occasionally bleeding may interfere with the procedure.
- In case of tight stricture, precluding the advancement of the scope with the probe, a Savary dilatation may be helpful.
- Edema and inflammation secondary to the treatment can temporarily worsen the dysphagic symptoms of the patients in the case of esophageal stents.

TIPS AND TRICKS

- Do not apply energy for too long and focally at the same (stent) location.
- Avoid over-distention of GI segments below the stricture.
- Avoid using the probe in a blind manner if the stricture does not allow for the discrimination of anatomical landmarks.
- Repeated sessions at 2 to 3-day intervals may be required.
- Soft diets or liquids are suggested in between the treatments until the GI lumen is completely recanalized.

14.8 STENT TRIMMING – APC

General description

In the case of distal bilio pancreatic cancer, access to the bile duct may be required in patients with previously positioned metal stents that may preclude access to the papillary area. Trimming of the stent with APC can be useful to open an orifice that allows further biliary cannulation and required interventions. "Trimming" means cutting and destroying the metal wire meshes of the self-expanding stents.

Fig. 14.16 Stent trimming using APC

Common settings

MODE	FORCED APC®
SETTING	60 – 80 W

Workflow

STEP 1	Place the distal end of the APC probe in close contact with the wire to be cut through
STEP 2	Activate the APC probe on the wire mesh. During activation, the RF current flows across the wire resulting in strong heating and the wire melts due to high electrical conductivity of the wire
STEP 3	Repeat step 2 for each wire mesh until the overlaying ends of the desired part of the stent are cut off and the papillary orifice is accessible

Pitfalls

- Diffusion of argon gas leading to emphysema. This can be avoided by non-direct tissue contact of the APC probe and by using an argon flow that is as low as possible (< 1.0 l/min).
- Precise application of APC to avoid unwanted stent breaking at the wrong place.
- Point-by-point stent trimming can be completed with wire rupture using foreign body forceps.
- Balloon dilation of the mesh opening can increase the potential for further maneuvers.

TIPS AND TRICKS

- APC is not recommended for the shortening of plastic stents.
- APC is applicable for the trimming of coated metal stents but needs to be tested individually.
- Use of a lateral-view scope is recommended.
- PRECISE APC mode from Erbe is not recommended for stent trimming!

14.9 TUMOR ABLATION IN THE ESOPHAGUS – APC

General description

Argon Plasma Coagulation (APC) is one therapy option for the treatment of Barrett's esophagus. Barrett's is a precancerous state with respect to Barrett's carcinoma. Using the argon plasma beam, the metaplastic Barrett's mucosa is ablated and, afterwards, native mucosa is recovered. Normally, unifocal Barrett's carcinoma are treated by endoscopic resection (ER) followed by thermal ablation of the remaining Barrett's epithelium.

Fig. 14.17 ← Barrett's esophagus before APC treatment.
→ Barrett's esophagus after APC treatment

Common settings

MANUFACTURER	Erbe Elektromedizin GmbH, Tübingen
INSTRUMENT	Straight fire or C-probe
MODE	PULSED APC®
SETTING	40–50 W, Effect 2

Workflow

STEP 1	Start on distal portion (5 mm below the gastroesophageal junction)
STEP 2	Movement of APC probe in longitudinal and/or circumferential lines on the target Barrett's tissue – dynamic application
STEP 3	Repeat until all Barrett's mucosa is ablated (generally several sessions are necessary)

Pitfalls

- Stricture formation.
- Thermal damage of the esophagus may lead to pain (swallowing).

TIPS AND TRICKS

- APC is not accepted as a primary therapy option alone. Argon plasma ablation of the Barrett's mucosa is used as secondary therapy after endoscopic resection of all early neoplasia (HGD, early Barrett's cancer).
- Intestinal metaplasia: recurrence (5 yrs): 30 %
- Thermal procedures are acceptable for high grade dysplasia or early carcinoma if EMR or operation is not possible.

14.10 ABLATION OF BARRETT'S ESOPHAGUS USING HYBRIDAPC

General description

Thermal ablation techniques, such as radio frequency ablation (RFA) or argon plasma coagulation (APC), have been shown to be effective in Barrett's esophagus. However, stricture formation is reported to occur in 5 – 15 % of patients treated.
The HybridAPC probe is a combination of the well-known APC function with the possibility of submucosal injection of fluid (NaCl 0.9 %) prior to ablation. After submucosal injection using a waterjet system, the remaining non-neoplastic Barrett's mucosa is ablated dynamically using APC within the same probe without the need for changing instruments. Due to the fluid cushion created by submucosal injection, the muscle layer is effectively protected from thermal alteration and thus the probability of stricture formation is greatly reduced.

Fig. 14.18 Treatment of Barrett's esophagus using the HybridAPC probe ← Demarcation of the lesion ↑ Submucosal injection → Thermal ablation using the APC function

ARGON PLASMA COAGULATION (APC)

Common settings

MANUFACTURER	Erbe Elektromedizin GmbH, Tübingen
INSTRUMENT	HybridAPC probe
MODE	PULSED APC®
SETTING	60 W, Effect 2

Workflow

STEP 1	Start on distal portion
STEP 2	Injection (elevation) of Barrett's mucosa (waterjet effect 30)
STEP 3	Dynamic movement of the APC probe longitudinally or circumferentially in the esophageal lumen. A change of instrument from step 2 to step 3 is not necessary. Additional injection may be performed on demand. Scrape off the debris with a transparent endoscopic cap. Repeat ablation of remaining visible Barrett's mucosa with a lower power of 40–50 W.
STEP 4	Repeat until all Barrett's mucosa is completely ablated (on average 2 – 3 sessions)

Pitfalls

- In order to avoid stricture formation, do not ablate more than 180° of the circumference per session, especially in the case of lesion size C = 3 cm or larger – even though meticulous injection has been carried out before the procedure.
- Post procedural pain (< 5 %).

TIPS AND TRICKS

- In early Barrett's cancer it should be kept in mind that resection is a first line therapy: all neoplasia should first be endoscopically resected. Then, thermal ablation by APC of the non-neoplastic remainder of the Barrett's segment is carried out.
- Fluid and gas should be removed from the stomach during the treatment to prevent extensive distension.

14.11 SUMMARY OF COMMON SETTINGS FOR APC IN GIT

PROCEDURE	POWER SETTING*	MODE*
Coagulation		
Barrett's esophagus	30 – 50 W 60 W (HybridAPC) under investigation	PULSED Effect 2
Small polyps	10 – 30 W	PULSED Effect 1
Devitalization after polypectomy or EMR, residual adenomas	20 – 30 W	PULSED Effect 1
Zenker's diverticulum	40 – 50 W	PULSED Effect 1
Radiation proctitis	10 – 30 W	PULSED Effect 2
Hemostasis		
Vascular malfunctions stomach / colon	10 – 30 W	PULSED Effect 2
Vascular malfunctions duodenum / right colon	Effect 4 – 5	PRECISE
Bleeding ulcer, Forrest Ib – IIb	30 – 60 W	FORCED
Tumor ablation		
Large (> 15 mm)	> 60 W	FORCED
Small (< 15 mm)	20 – 50 W	FORCED
Stent management		
Stent ingrowth / overgrowth	20 – 30 W	PULSED Effect 2
Stent trimming	30 – 60 W	FORCED

* Erbe APC® 2 unit

14.12 APC COMPLICATIONS

- Scars / strictures vs. ineffective ablation
- Burns / neutral electrode
- Perforation
- Explosion
- Damage of endoscope

Preventive Strategies

COLON EXPLOSION	RADIATION PROCTITIS
1. Bowel cleansing 2. Cleansing agents 3. Proper time for intestinal cleansing 4. Aspiration / lowering of the methane / hydrogen gas concentration 5. Displacement of methane / hydrogen	1. Only orthograde, complete bowel preparation 2. Retrograde preparation is not sufficient! 3. Mannitol is obsolete 4. If possible, prepare on same day of the intervention

14.13 TEN SUGGESTIONS FOR USING APC IN DIFFERENT SETTINGS

1. START WITH COMMON SETTINGS
2. THERMAL EFFECTS DEPEND ON THE DURATION OF ACTIVATION AND THE OUTPUT SETTING
3. DIFFERENT WALL THICKNESS IN GIT
4. ALWAYS UNDER VISUAL CONTROL (TIP AND BLACK RING)
5. ONLY SHORT ACTIVATION TIMES (FOR STATIC APPLICATIONS)
6. ACTIVATE DURING RETRACTION (FOR DYNAMIC APPLICATIONS)
7. AVOID DIRECT TISSUE CONTACT
8. DO NOT PRESS THE APC PROBE INTO THE TISSUE
9. WATCH OUT FOR METAL CLIPS/METAL INSTRUMENTS (PRECISE)
10. OXYGEN LEVEL < 40 % (BRONCHOSCOPY)

DRAINAGE OF PANCREATIC CYSTS

General description

Pancreatic cysts are collections of liquid within the head, body or tail of the pancreas, mainly after pancreatitis. The size of the cysts can range from millimeters to several centimeters. Many cysts are infected but there are also cysts without infections. Pancreatic cysts can be treated by endoscopic means or surgically. Access to the cyst is achieved by endoscopic ultrasound (EUS) and puncture with a 19G needle and a guide wire, which is maneuvered into the cyst. Special needle knives are used for cutting the gastrointestinal wall and allowing access to the cyst for drainage implantation.

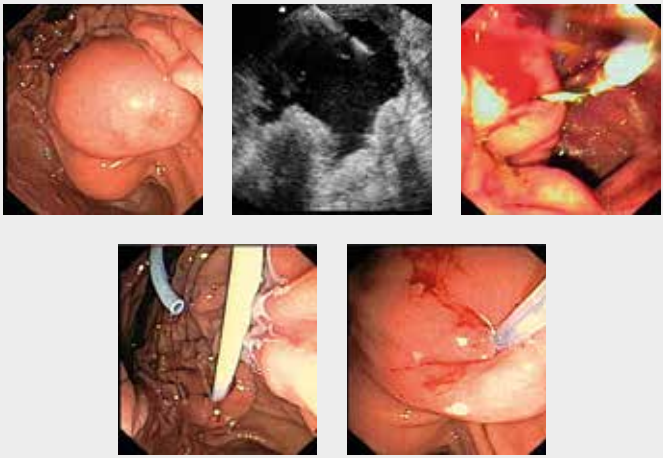

Fig. 15.1 Endoscopic treatment of a pancreatic pseudocyst using a 19G needle and a cystostome

Recommended settings

METHOD	Needle-knife cystotome or short-nose standard sphincterotome
CURRENT MODE	Alternating cutting and coagulation: ENDO CUT®, blended current
SELECTED SETTINGS	ENDO CUT® Effect 2/3 FORCED COAG 40–50 W, Effect 2

DRAINAGE OF PANCREATIC CYSTS

Workflow

STEP 1	Depict the lesion and mark the appropriate access route by EUS
STEP 2	Puncture with a 19G EchoTip® needle and place a guide wire. Alternatively, use direct cutting with a dedicated EUS-guided cystotome
STEP 3	Facilitate opening of the gastrointestinal wall and access to the cyst
STEP 4	Implant drainage devices via the echoendoscope under fluoroscopic and ultrasound view

Pitfalls

- Appropriate visualization of the cyst is sometimes difficult, as is getting the correct angle of the EchoTip® needle.
- Bleeding after cutting due to extraluminal vessels of the gastrointestinal wall.
- Losing adequate ultrasound vision after reaching the cyst.
- Incorrect angle of the access route into the cyst, distance between GI wall and cyst > 1 cm.

TIPS AND TRICKS

- Check for vessel within the puncture/cutting direction of the needle knife.
- Straight access of the needle knife into the cyst, usually via the lesser curve of the stomach or duodenum.
- Implantation of double-pigtail drainage device easier and more efficient than straight prostheses, mainly > 1 drainage.
- Temporary placement of dedicated "umbrella" metallic stents for special cases before necrosectomy.

NATURAL ORIFICE TRANSLUMINAL ENDOSCOPIC SURGERY (NOTES)

General description

In recent years, Natural Orifice Transluminal Endoscopic Surgery (NOTES) was evaluated in many basic studies and entered clinical practice for a few dedicated indications. Here, natural orifices via stomach, rectum, bladder and vagina are used to pass through for an internal incision into peritoneal or thoracic spaces. NOTES procedures have been realized so far for cholecystectomy, distal pancreatectomy, splenectomy, adrenalectomy, bowel resection and gastrointestinal anastomosis in pilot studies using the swine model. Since transabdominal incisions are replaced by internal transvisceral incisions, patients could benefit mainly from less postoperative pain, faster wound healing, less scarring and accelerated patient recovery. Risks of the procedure are related to infections and security of visceral closure. Further research activities are ongoing regarding the development of "pure" NOTES approaches including multitasking NOTES platforms. Currently, most NOTES procedures are deployed as "hybrid" methods since, in the clinical routine, NOTES operations require laparoscopic assistance for visualization, retraction and dissection. Electrosurgery using laparoscopic and endoscopic instruments is applied on different levels for tissue dissection and control of bleeding. Only when new platforms and endoscopes are available in the near future can pure NOTES be recommended for routine use.

NATURAL ORIFICE TRANSLUMINAL ENDOSCOPIC SURGERY (NOTES)

Fig 16.1 NOTES prototype platforms under development:
↖ Anubis® platform from Karl Storz
↗ Transanal Endoscopic Operations device, Karl Storz

Workflow (as evaluated in pilot animal trials)

STEP 1	Detection of diseased tissue or organ with specified diagnosis tools
STEP 2	Insufflation of gas (CO_2) to create a pneumoperitoneum, if necessary
STEP 3	Introduction of NOTES platform devices and instruments into natural orifice
STEP 4	Incision of organ depending on specified route
STEP 5	Resection of diseased tissue or organ
STEP 6	Retrieval of specimen
STEP 7	Closure of incision
STEP 8	Retraction of NOTES platform devices and instruments

Pitfalls

- Risk of internal bleeding (e.g. intraperitoneal hemorrhage).
- Closure of the internal incision is a source of postoperative complications.
- Surgical infection due to bacteria, especially in the transcolonic route, may lead to delayed wound healing and regeneration.
- Risk of thermal injuries due to electrosurgery.

TIPS AND TRICKS

- Only the transvaginal access for cholecystectomy is currently considered as safe and feasible, and is being performed routinely.
- Transgastric appendectomy also seems to be safe and beneficial in humans (TGA study).

16.1 TRANSESOPHAGEAL INTERVENTIONS – POEM

General description

Peroral endoscopic myotomy (POEM) represents the culmination of natural orifice transluminal endoscopic surgery (NOTES) research and its most successful application to date. Several thousands of POEMs have been performed globally as of late 2015, with remarkable results in terms of clinical efficacy and safety. The procedure combines submucosal injection and tunnelling to ultimately dissect the inner circular muscle fibers associated with achalasia types as well as spastic esophageal disorders. Hemostatic clips or OverStitch devices are used to close the entry site and the mucosal flap in the esophagus.

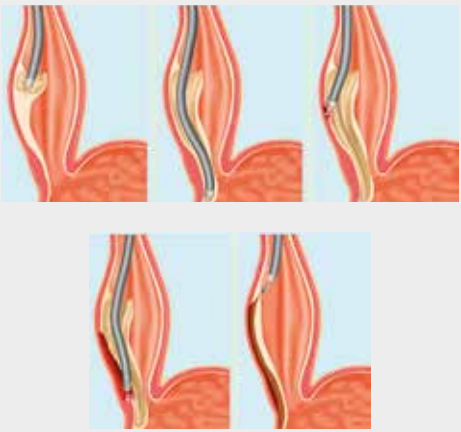

Fig. 16.2 Schematic view of Peroral Endoscopic Myotomy (POEM) Incision ↖, submucosal tunnelling ↑ and myotomy ↗ using Triangle Tip Knife
↙ Endpoint of myotomy at GEJ ↘ and closure of mucosal entry Source: Inoue et al. Endoscopy 2010; 42:265-271

Fig. 16.3 ←Endoscopic view of myotomy in the submucosal tunnel and →completion of dissection of circular muscle bundles
Source: Inoue et al. Endoscopy 2010; 42:265-271

Common settings

SUB-STEP OF THE PROCEDURE	SETTING
Mucosa elevation	ERBEJET® 2 Effect 30 – 60
Creation of the submucosal tunnel using Triangle Tip Knife (Olympus)	
Step 1 Incision on mucosa surface	VIO® 300 D: DRY CUT® 50 W, Effect 3
Step 2 Extension of submucosal tunnel	VIO® 300 D: SWIFT COAG® or ENDO CUT® Q, DRY CUT® 80 – 100 W, Effect 2
Dissection of circular muscle using Triangle Tip Knife (Olympus) or knife of choice	VIO® 300 D: ENDO CUT® Q SPRAY COAG 50 W, Effect 2*

* Source: Inoue et al. Endoscopy 2010; 42:265-271

NATURAL ORIFICE TRANSLUMINAL ENDOSCOPIC SURGERY (NOTES)

Workflow

STEP 1	Orientation and assessment of proper mucosal incision site based upon anatomy, achalasia type and stage
STEP 2	Submucosal injection (e.g. saline + 0.3 % indigo carmine) to create significant cushion
STEP 3	Incision using the Triangle Tip Knife (Olympus) or knife of choice
STEP 4	Submucosal tunnelling
STEP 5	Dissection of the circular muscle fibers down and through the gastroesophageal junction and 2–3 cm into the stomach
STEP 6	Examination of the complete circular muscle dissection with the endoscope to determine efficacy of the procedure
STEP 7	Closure of the entry site using hemostatic clips or OverStitch device

Pitfalls

- Leakage of mucosal closure resulting in infection.
- Post procedure bleeding within the tunnel.
- Correct navigation and maneuvering to access the circular muscle layers of the lower esophageal sphincter.
- Losing orientation and inadvertent injury to structures outside the esophageal lumen.

16.2 NOTES PROCEDURES – TRANSVAGINAL INTERVENTIONS CHOLECYSTECTOMY

General description

Cholecystectomy is the most frequently performed NOTES procedure. Up to now, the transvaginal NOTES access route has been selected in the majority of cases. Usually, the method is performed as a "hybrid" NOTES procedure using a transumbilical trocar for laparoscopic support of the operation procedures carried out by the vaginal natural orifice. Important dissection steps that involve Calot's triangle preparation and electrosurgery for gall bladder mobilization are carried out through the laparoscopic trocar. Tissue is retracted using an extraction bag through the vaginal trocar. Closure of the vaginal orifice is performed by suturing.

Fig 16.4 ← Calot's triangle preparation ↑ Cystic duct dissected between two endoclips → Separation of gall bladder from liver bed using hot biopsy forceps

NATURAL ORIFICE TRANSLUMINAL ENDOSCOPIC SURGERY (NOTES)

Common settings

No reliable and accepted reports on generator settings presented so far.

Workflow

STEP 1	Establishment of a pneumoperitoneum
STEP 2	Localization of a position for the umbilical trocar (including camera support) insertion and control of the endoscopic positioning in the gall bladder area
STEP 3	Accomplishment of the vaginal incision and insertion of endoscope
STEP 4	Dissection of Calot's triangle using hot forceps or Harmonic scalpel
STEP 5	Ligature of the cystic duct using PolyLoop™ or endoclips
STEP 6	Dissection of the cystic duct using endoscissors or Harmonic scalpel
STEP 7	Cystic artery sectioning by clipping or coagulation, if possible using Harmonic scalpel
STEP 8	Retrieval of gall bladder using polypectomy snare
STEP 9	Transvaginal withdrawal of specimen using snare
STEP 10	Closure by suturing

Pitfalls

- Risk of intraoperative bleeding (cystic artery).
- Risk of compression syndrome due to gas insufflation.
- Possibility of internal organ injuries (bladder, rectum, small bowel).
- Possibility of Douglas abscess (drainage: vaginal or laparoscopic).
- Uncontrolled bleeding bears the risk of infertility.

Remarks

The complications were present only in low incidence rates.

16.3 ENDOSCOPIC FULL-THICKNESS RESECTION (EFTR) IN THE COLORECTUM USING THE FTRD SYSTEM

General description

Endoscopic full-thickness resection (EFTR) is an evolving technique allowing endoscopic treatment of lesions that are difficult or impossible to resect with conventional methods like endoscopic mucosal resection (EMR) or endoscopic submucosal dissection (ESD). The main indications for EFTR are non-lifting colorectal neoplasms (e.g. recurrent adenomas), lesions located at difficult anatomic sites (diverticula, appendiceal orifice) and subepithelial tumors.

The novel "full-thickness resection device" (FTRD, Ovesco Endoscopy, Tübingen, Germany) was designed for one-step colonic EFTR after application of an over-the-scope clip (OTSC). Similar to the conventional OTSC system, it can be mounted over a standard colonoscope. The system consists of a long transparent applicator cap carrying a modified 14 mm OTSC. Compared to the conventional OTSC system, the cap is much longer (23 mm vs. 6 mm) and, therefore, can grasp more tissue. A 13 mm monofilament radio frequency (RF) snare is preloaded in the tip of the cap. The handle of the snare runs on the outer surface of the scope underneath a plastic sheath (see Figure 16.5).

For resection, grasping forceps (or a tissue anchor) are advanced through the working channel of the endoscope and the lesion is pulled into the cap thereby creating a full-thickness duplication of the colonic wall (see Figure 16.6). Immediately after clip deployment, the tissue above the clip is resected with the snare above the clip. The clip is thereby securing the colonic wall's patency.

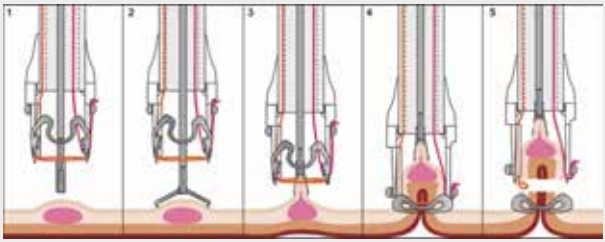

Fig 16.5 Technique of EFTR with the FTRD
1: The device is advanced to the lesion.
2: Grasping forceps are advanced through the working channel of the endoscope.
3: The lesion is grasped and pulled into the cap.
4: The clip is deployed.
5: The tissue above the clip is resected with the snare.

Fig 16.6 Endoscopic full-thickness resection of a non-lifting recurrent adenoma in the descending colon.

← Non-lifting adenoma in the descending colon
↑ Aspect of the lesion using Narrow Band Imaging (NBI); the lesion is marked circumferentially with an RF-probe or using APC.
→ Endoscopic view with the mounted FTRD system

← The lesion is pulled into the cap.
↑ Resection site; the OTSC is securing the colonic wall's patency
→ EFTR specimen

NATURAL ORIFICE TRANSLUMENAL ENDOSCOPIC SURGERY (NOTES)

Common settings

SUB-STEP OF THE PROCEDURE	SETTING
Marking the lesion with RF-probe	**FORCED COAG,** 20 W, Effect 1
Resection	**ENDO CUT® Q*,** Effect 1 Cutting duration 4 Cutting interval 1

* Additional settings for cutting duration and cutting interval are adjustable in expert mode only

Workflow

STEP 1	Identification of the lesion (without the FTRD system) and marking of the lesion
STEP 2	Advancing the endoscope with the mounted FTRD system to the lesion, grasping the lesion with forceps and pulling the lesion into the cap
STEP 3	Deployment of the clip
STEP 4	Immediate closure of the snare and harvesting of the resection specimen
STEP 5	Inspection of the resection site

Pitfalls

- Advancing the scope with the mounted FTRD through the sigmoid or beyond the colonic flexures may be difficult.
- In case of severe scarring or resections in the lower rectum, pulling of the tissue into the cap may be difficult.

TIPS AND TRICKS

- Marking of the lesion with the RF-probe is mandatory to facilitate identification of the lesion.
- In case of difficult advancement of the FTRD to the target lesion, change of the patient's position or use of X-ray may be helpful.
- Do not use suction to pull the tissue into the cap.
- In case of subepithelial tumors, a tissue anchor instead of grasping forceps should be used to pull the lesion into the cap.
- After OTSC deployment, it is important to immediately close the snare to prevent loss of the correct resection position.
- Inspection of the resection site is mandatory to exclude local complications after resection.

THE ERBE HYBRIDKNIFE®

A smart opportunity for en bloc resection of early carcinoma in the gastrointestinal tract.

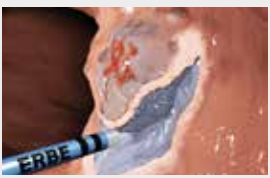

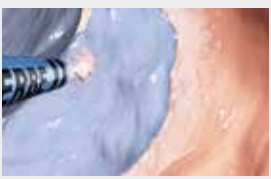

Erbe Elektromedizin GmbH
Waldhoernlestrasse 17
72072 Tuebingen
Germany

support@erbe-med.com
erbe-med.com

85800-13503.16